ALLERGIC CONJUNCTIVITIS

1. Allergic rhinoconjunctivitis
2. Vernal keratoconjunctivitis
3. Atopic keratoconjunctivitis

Allergic rhinoconjunctivitis

- Hypersensitivity reaction to specific airborne antigens
- Frequently associated nasal symptoms
- May be seasonal or perennial

Transient eyelid oedema

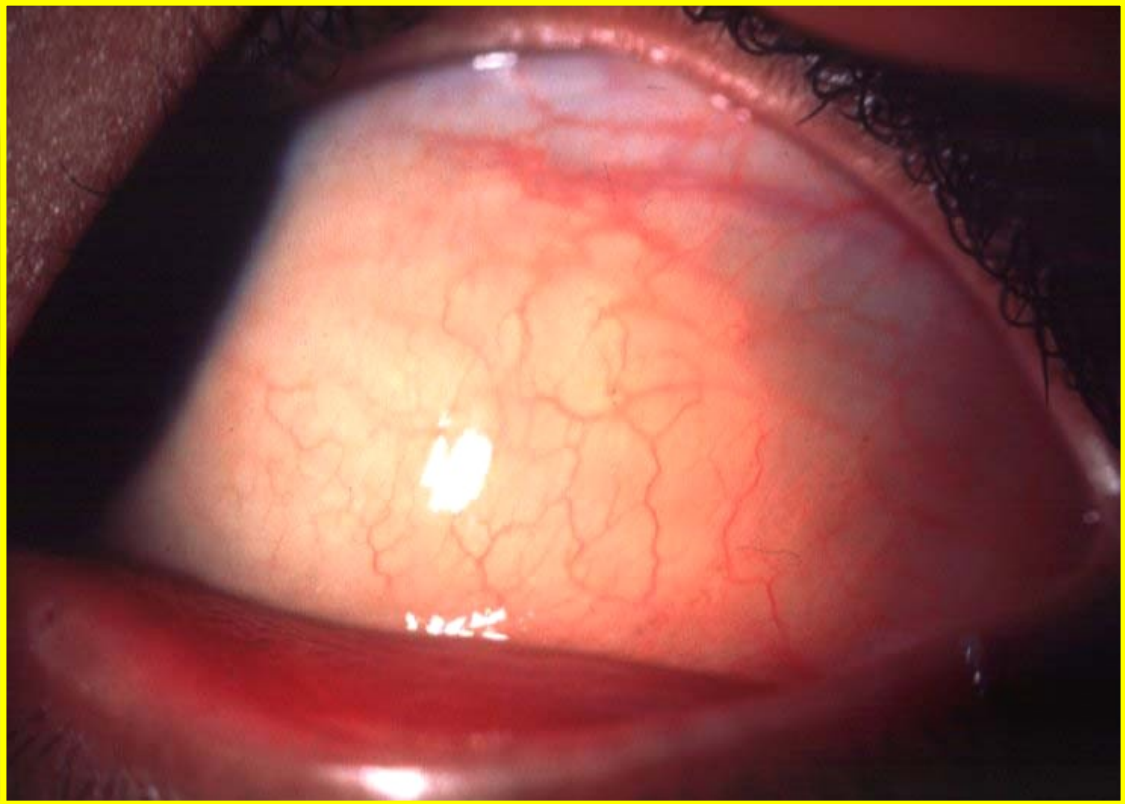

Transient conjunctival oedema

Vernal keratoconjunctivitis

quently associated with atopy: asthma, hay fever and dermatitis

- More common in males and in warm climates

Types

Treatment

Progression of vernal conjunctivitis

Diffuse papillary hypertrophy, most marked on superior tarsus



Formation of cobblestone papillae

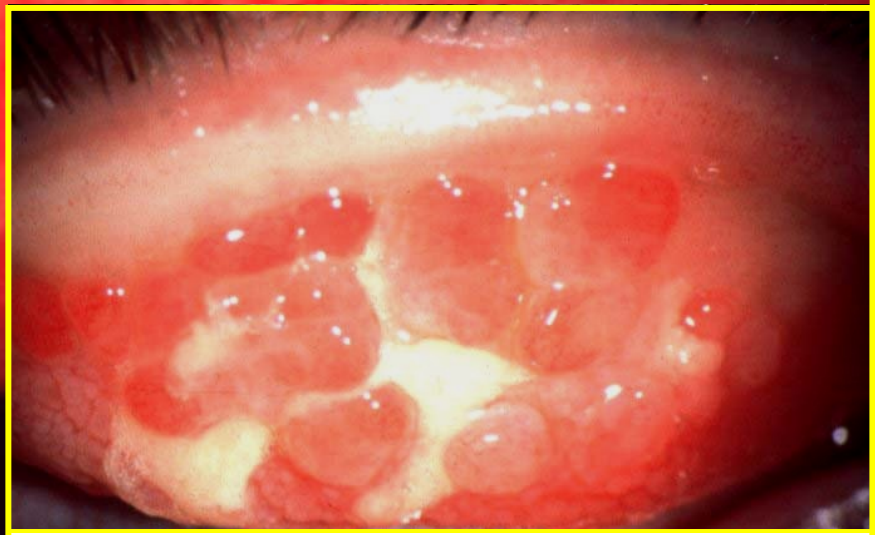

Rupture of septae → giant papillae

Limbal vernal

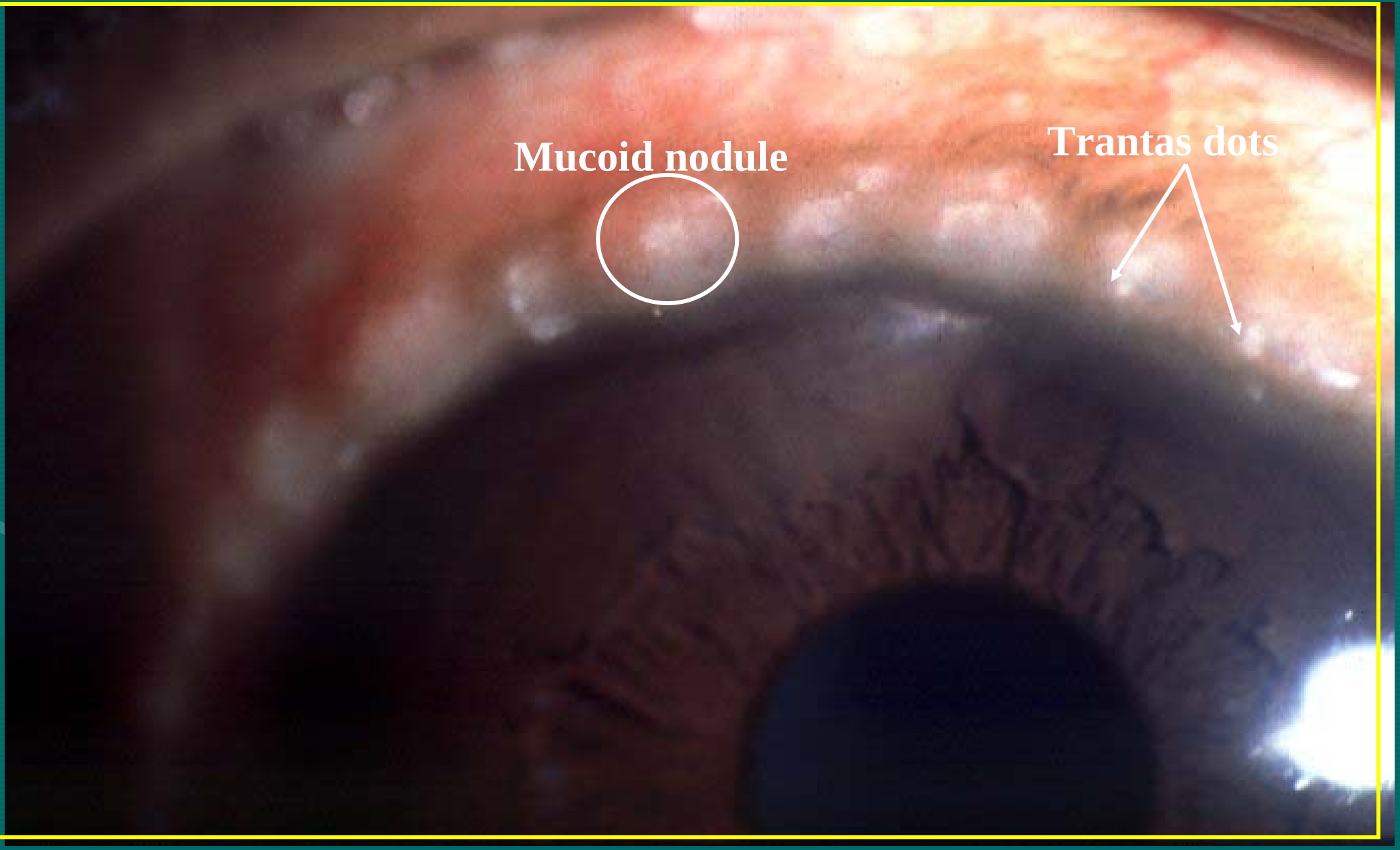

Progression of vernal keratopathy

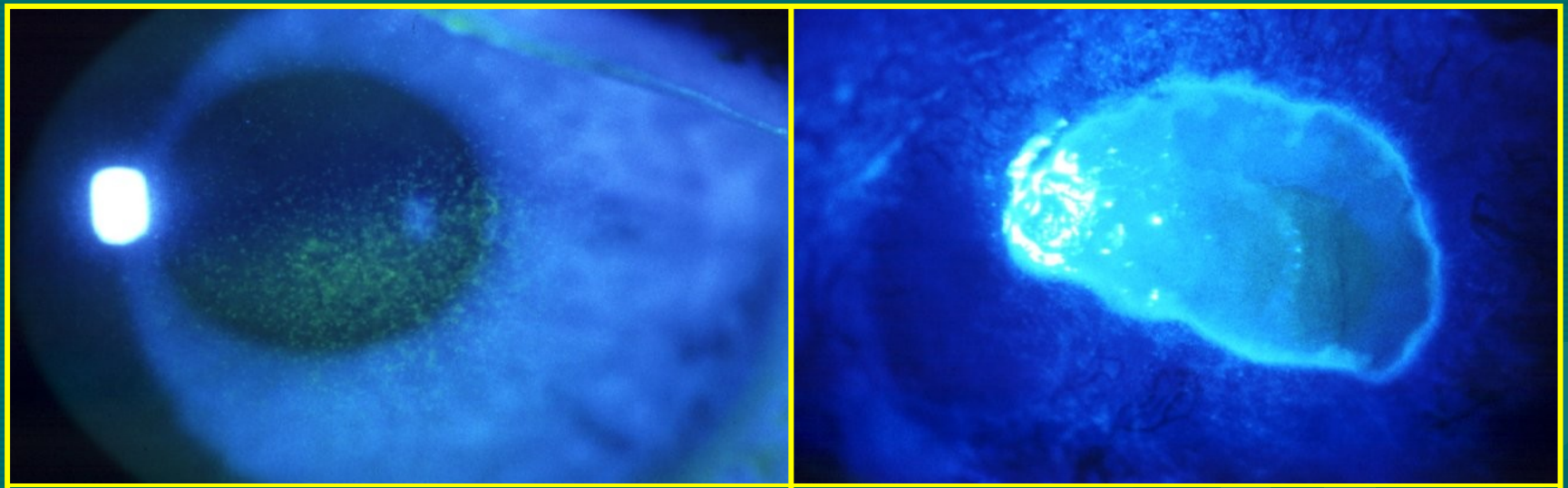

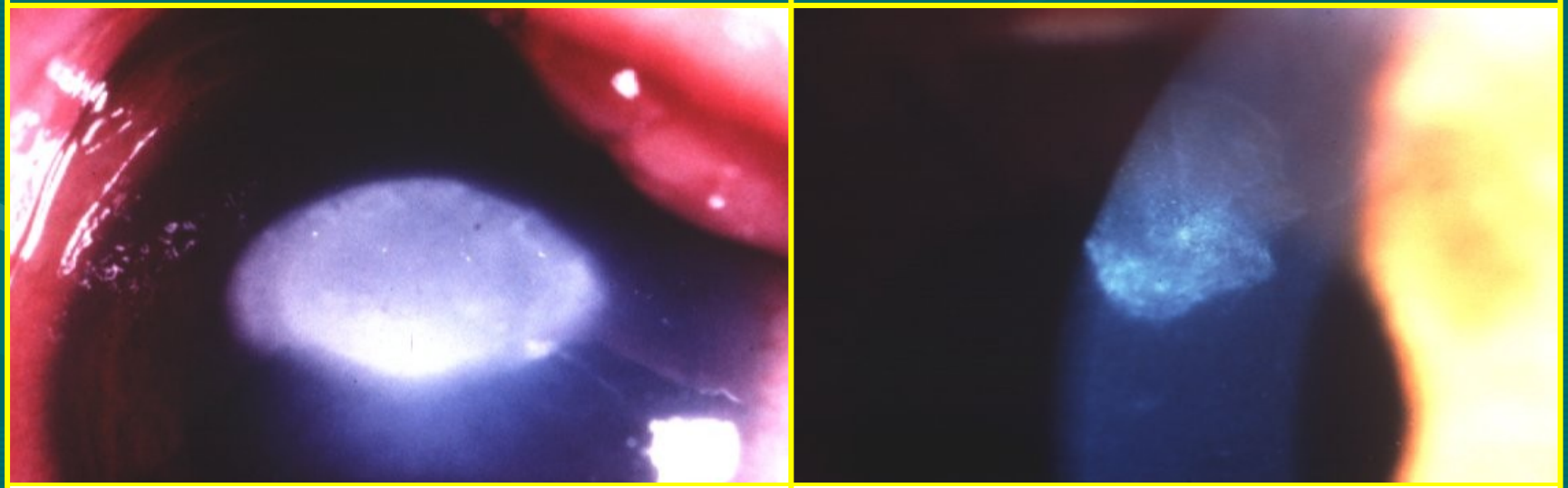

Plaque formation (shield ulcer)

Subepithelial scarring

Atopic keratoconjunctivitis

Typically affects young patients with atopic dermatitis

Lids are inflamed, thickened, macerated and fissured

Progression of atopic conjunctivitis

Infiltration of tarsal conjunctiva causing featureless appearance

Inferior forniceal papillae

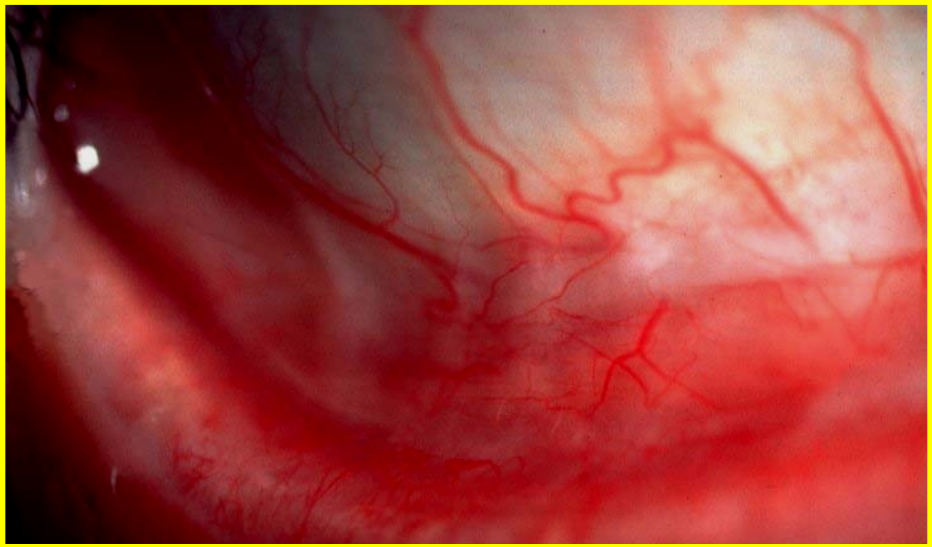

Mild symblepharon formation

Progression of atopic keratopathy

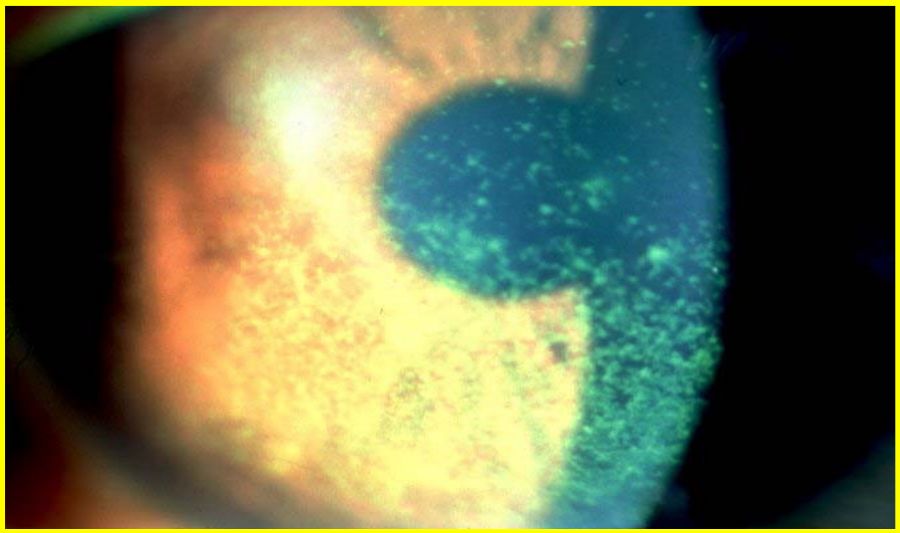

Punctate epithelopathy

Persistent epithelial defects

Subepithelial scarring

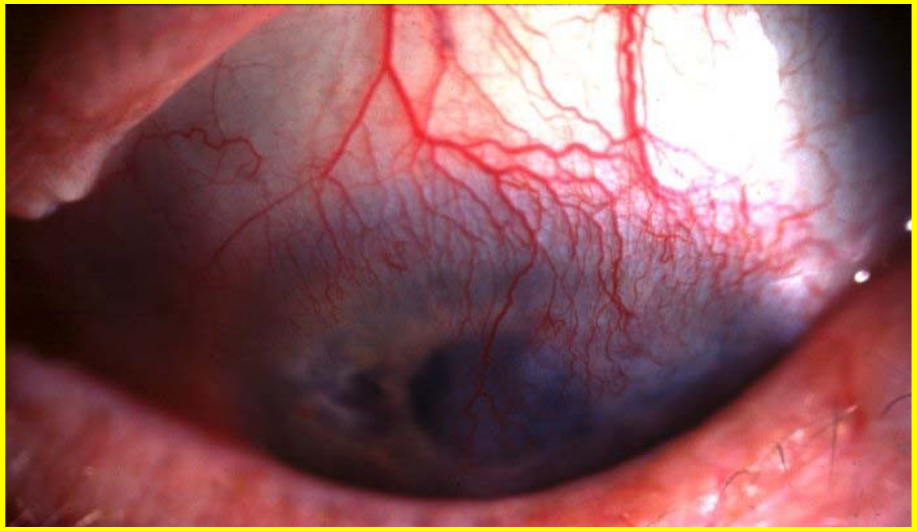

Peripheral vascularization